

Original Research Article

A prospective study on the efficacy of platelet rich plasma in alopecia areata

Ravichandran Velappan, Kamalanathan Nallu*, Sindhuja Ramasamy, Muthusubramanian Chandrasekar

Department of Dermatology, Chengalpattu Medical College, Tamil Nadu, India

Received: 16 April 2019

Accepted: 02 May 2019

***Correspondence:**

Dr. Kamalanathan Nallu,

E-mail: drnkamalmd@gmail.com

Copyright: © the author(s), publisher and licensee Medip Academy. This is an open-access article distributed under the terms of the Creative Commons Attribution Non-Commercial License, which permits unrestricted non-commercial use, distribution, and reproduction in any medium, provided the original work is properly cited.

ABSTRACT

Background: Alopecia areata is an inflammatory auto-immune disease mainly affecting the scalp and other hair bearing areas. Platelet rich plasma contains concentrated platelets (more than that present in whole blood). Due to the presence of high concentration of growth factors, PRP is used in various conditions in the field of medicine and surgery. The aim of the study was to evaluate the efficacy of platelet rich plasma in alopecia areata.

Methods: 20 patients, 16 male and 4 female with alopecia areata were enrolled in the study. PRP was injected in the alopecia sites for a total of 4 sessions every 28 days. Patients were followed in every month for 6 months and then at the end of one year. Pre and post treatment response was noted.

Results: 13 patients responded well to treatment (65%), moderate response was seen in 3 (15%) patients and 4 patients showed no response (20%). 2 patients had relapse at the end of the study (10%).

Conclusions: PRP was found to be an effective treatment modality for alopecia areata.

Keywords: Non-scarring hair loss, Growth factors, SALT score

INTRODUCTION

Alopecia areata (AA) is a common, autoimmune disease that affects the hair-bearing areas including the scalp, face and other areas of the body resulting in non-scarring hair loss.¹ It is the most common inflammatory cause for hair loss. It clinically manifest as patchy hair loss, which can progress to complete loss of hair from the scalp, alopecia totalis (AT) or from the whole body, alopecia universalis (AU).² Peribulbar inflammatory lymphocytic infiltrates with increased number of catagen and telogen hairs is seen in histopathology.³ The disease commonly affects the young and hence may lead to significant psychological stress, loss of self-esteem and depression.⁴

Spontaneous remission can be seen which varies according to the individuals. The main aim of treatment is

to control the disease activity. Various treatment modalities are available for alopecia areata. This includes topical and systemic steroids, topical minoxidil, PUVA, immunosuppressives like cyclosporine, methotrexate, azathioprine and biologicals like tofacitinib.

Platelet-rich plasma (PRP) contains autologous platelets in concentrated plasma. It has been used in several conditions for its role in wound healing.⁵ The exact mechanisms by which PRP exerts its effects on hair follicles is not known. PRP contains a multitude of growth factors and believed to exert its action by recruitment of reparative cells. PRP stimulates the proliferative phase of hair follicle and differentiation of hair stem cells and hence may produce new follicular units. The aim of our study was to evaluate the treatment response to PRP in alopecia areata.

METHODS

This is a prospective study that was conducted at Chengalpattu Medical College Hospital, Chengalpattu from April 2018- March 2019. After obtaining institutional ethical committee approval, 20 patients with clinical or biopsy proven AA who attended the outpatient department were enrolled in the study. Inclusion criteria were patients above 18 years of age and of both sexes and those willing for the procedure. Exclusion criteria included pregnant and lactating mothers, patients on long term immuno-suppressives or on chemotherapy or with other causes of alopecia, patients with history of bleeding disorder, on anticoagulant medications (aspirin, warfarin, heparin), patients with active infection at procedure site, patients with keloidal tendency and patients with AT or AU. No particular randomisation done since all of them were healthy young adults.

Detailed history including demographic, disease duration and progression, treatment taken, family, past medical and surgical history were taken. Systemic examination to rule out systemic causes of alopecia was done. Other scalp or hair disorder causing alopecia was ruled out. The number and symmetry of the patches were noted. Complete blood count, bleeding time, clotting time, blood Sugar, fasting thyroid profile was done for all patients.

All the patients were explained about the procedure in detail. An informed consent form was signed by each patient. PRP was prepared from patient’s own blood, which was drawn at the time of treatment.

A volume of 25 ml blood was taken from each patient and sent to lab for preparation of PRP. 25ml of blood yielded 3-4 ml of PRP. PRP solution obtained from the lab was used within 30 min of its preparation. It was injected in the area of alopecia in the subfollicular plane after local anaesthetic application. Patients vitals were checked before and after the procedure. Patients were reviewed at the end of 4 weeks. All the patients received 4 sessions of PRP at 4 weekly intervals. Patients were reviewed every month for 6 months and then at the end of 1 year. Clinical improvements and side effects if any were noted. Pre and post treatment response was assessed by SALT (Severity of Alopecia Tool) score. Appropriate inferential and descriptive statistical analysis was done.

RESULTS

Of the 20 patients, 16 were male and 4 female (Figure 1). The age of the patients was from 22-38 years of age (mean 27.8). All patients had normal blood investigations. The number of patches varied from 1-4 (Figure 2). All patients had sudden onset of hair loss with the duration ranging from 20-120 days (mean 75.3). 9 patients had progressive hair loss (45%) and 11 had a stationary course (55%). The mean SALT score before treatment was 38.9 and after treatment was 20.78 (Figure 3). 13 patients responded well to treatment (65%),

moderate response was seen in 3 (15%) patients and 4 patients showed no response (20%), (Figure 4 and 5). 2 patients had relapse at the end of the study (10%).

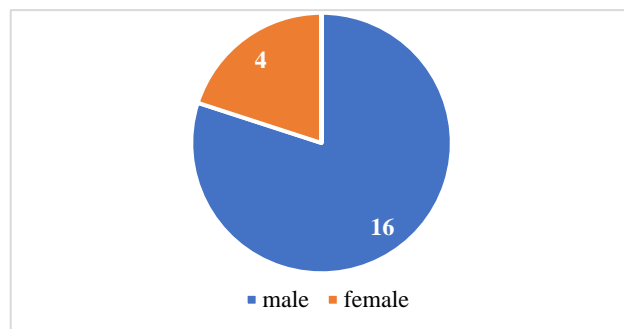


Figure 1: Sex distribution.

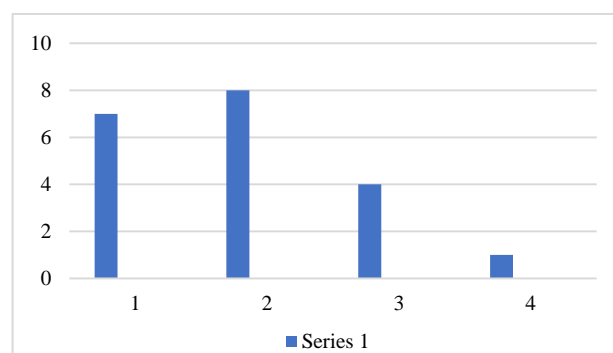


Figure 2: No. of patches.

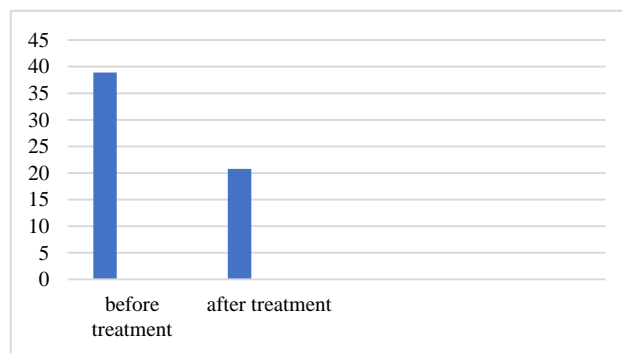


Figure 3: Mean SALT score.

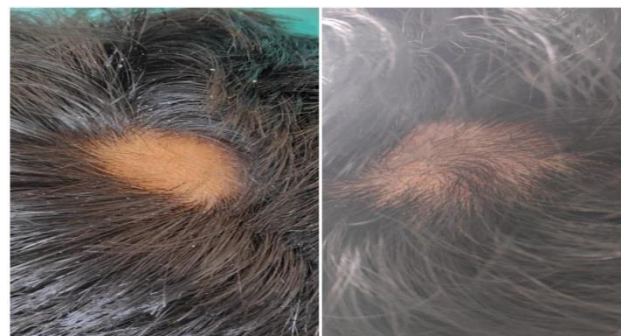

Figure 4: Before and after 4 sittings of PRP.

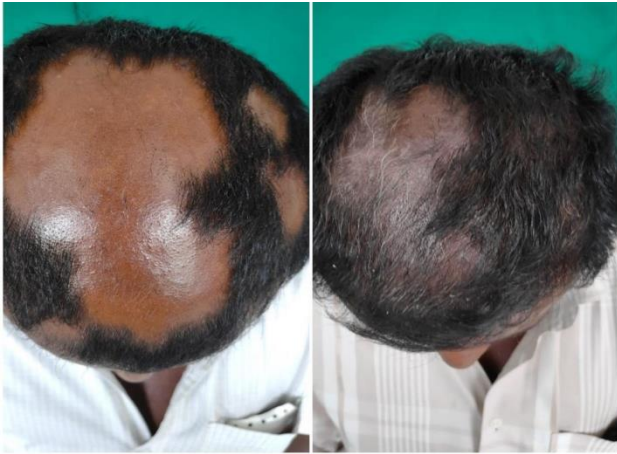

Figure 5: Before and after 6 sittings of PRP.

DISCUSSION

AA is an autoimmune disease due to the loss of the immune privilege of hair follicles resulting in rapid and complete loss of hair in one or more round to oval patches, usually on the scalp.⁶ Many treatments are available for AA, but none are curative or preventive.⁷

PRP contains abundant concentrated platelets in a small volume of plasma. PRP contains a multitude of growth factors that are stored as α -granules in platelets. They include PDGF, TGF, VEGF, EGF, HGF, FGF and plasma proteins- fibrin, fibronectin and vitronectin. The growth factors play a role in tissue repair and regeneration, and the plasma proteins act as a scaffold for the bone, connective tissue and epithelial migration.⁸ Degranulation resulting in the release of growth factors occurs upon "activation" of platelets.

PRP can be prepared manually or by automated devices. It should be prepared just prior to the procedure. It is prepared under strict aseptic conditions, with an optimal temperature of 20-22°C. Citrate dextrose solution formula A (ACD-A) or sodium citrate is used to prevent platelet aggregation.⁹

Manual double spin method

In this method, 'light-spin' centrifugation is used to separate platelet rich plasma from whole blood and 'heavy-spin' centrifugation is used for platelet concentration by removing the supernatant plasma." A platelet concentration of more than 1 million/ μ l (approximately four to seven times the mean levels) is necessary for therapeutic efficacy.¹⁰ Calcium chloride (CaCl_2) is used as an "activator" which triggers coagulation and results in the degranulation of growth factors. The active secretion of growth factor takes place within 10 minutes of clot initiation and 95% is completed within 1 hour.¹¹ Hence, necessitating the use of PRP within 10 minutes of activation.

Automated devices

Numerous commercial devices for the preparation of PRP are available which may be time saving, but they are expensive when compared to the manual method.

At the end of our study about 13 (65%) patients had a complete regrowth of pigmented hair, while 3 (15%) patients had partial and 4 patients (20%) had no regrowth of hair. In our study there was significant improvement in SALT score in 65% of the patients.

In one study, on the effectiveness of PRP in AA in a group of 30 patients, there was clinical improvement in 70% of patients. 30% of patients had partial or no regrowth of hair.¹² Their study also showed a significant difference of SALT score with treatment which is in concordance with our study. Though no relapse was noted in their study, our study had a relapse of 10%.

In another randomized, double-blind, placebo-and active-controlled, half-head study to evaluate the effects of PRP on alopecia areata, the results showed that PRP is a safe and alternative treatment for alopecia areata.¹³

CONCLUSION

AA is a disease most commonly occurring in the young adults hence has a large psychological and social impact. Since all the treatment available for AA as of now is associated with recurrences and relapses, PRP can be used as a cost effective and better treatment modality in the treatment of alopecia areata.

Funding: No funding sources

Conflict of interest: None declared

Ethical approval: The study was approved by the institutional ethics committee

REFERENCES

1. Gilhar A, Etzioni A and Paus R. Alopecia areata. N Engl J Med. 2012;366:1515-25.
2. Alsantali A, Alkhalifah A, Wang E, McElwee KJ, Shapiro J. Alopecia areata update: Clinical picture, histopathology, and pathogenesis. J Am Acad Dermatol. 2010;62:177-90.
3. El Darouti M, Marzouk SA, Sharawi. Eosinophils in fibrous tracts and near hair bulbs: a helpful diagnostic feature of Alopecia. J Am Acad Dermatol. 2000;42:305-7.
4. Finner AM. Alopecia areata: Clinical presentation, diagnosis, and unusual cases. J Am Acad Dermatol. 2011;24:348-54.
5. Marx RE, Garg AK. Dental and Craniofacial Applications of Platelet-Rich Plasma. Chicago: Quintessence Publishing; 2005.
6. Kakudo N, Minakata T, Mitsui T, Kushida S, Notodihardjo FZ, Kusumoto K. Proliferation promoting effect of platelet rich plasma on human

- adipose derived stem cells and human dermal fibroblasts. *Arch Dermatol Res.* 2008;122:1352-60.
7. Alkhalifah A. Topical and intralesional therapies for Alopecia areata. *Dermatol Ther.* 2011;24:355-63.
 8. Steed DL. The role of growth factors in wound healing. *Surg Clin North Am.* 1997;77:575-86.
 9. Arshdeep, Kumaran MS. Platelet-rich plasma in dermatology: Boon or a bane? *Indian J Dermatol Venereol Leprol.* 2014;80:5-14
 10. Weibrich G, Kleis WK, Hafner G. Growth factor levels in the platelet-rich plasma produced by 2 different methods: Curasan-type PRP kit versus PCCS PRP system. *Int J Oral Maxillofac Implants.* 2002;17:184-90.
 11. Kevy S, Jacobson M. Preparation of growth factors enriched autologous platelet gel. Proceedings of the 27th Annual Meeting of Service Biomaterials, April 2001.
 12. Kumar A, Sharma RP, Bali S, Arya P. Role of platelet rich plasma therapy in alopecia areata prospective study. *International Journal of Contemporary Medical Research* 2016;3(8):2499-502.
 13. Trink A, Sorbellini E, Bezzola P, Rodella L, Rezzani R, Ramot Y, et al. A randomized, double-blind, placebo-and active-controlled, half-head study to evaluate the effects of platelet-rich plasma on alopecia areata. *Br J Dermatol.* 2013;169:690-4.

Cite this article as: Velappan R, Nallu K, Ramasamy S, Chandrasekar M. A prospective study on the efficacy of platelet rich plasma in alopecia areata. *Int J Res Dermatol* 2019;5:583-6.