

## Original Research Article

# Evaluation of platelet-rich plasma on infraorbital dark circles by using the FACE-Q scales

Kadri Ozer<sup>1\*</sup>, Ozlem Colak<sup>2</sup>

Plastic, Reconstructive and Aesthetic Surgery Clinic, <sup>1</sup>Aydin State Hospital, Aydin, <sup>2</sup>Istanbul Okmeydani Training and Research Hospital, Istanbul, Turkey

**Received:** 21 January 2019

**Revised:** 03 March 2019

**Accepted:** 05 March 2019

**\*Correspondence:**

Dr. Kadri Ozer,

E-mail: [kadrioz@hotmail.com](mailto:kadrioz@hotmail.com)

**Copyright:** © the author(s), publisher and licensee Medip Academy. This is an open-access article distributed under the terms of the Creative Commons Attribution Non-Commercial License, which permits unrestricted non-commercial use, distribution, and reproduction in any medium, provided the original work is properly cited.

### ABSTRACT

**Background:** Infraorbital dark circles, also referred to as idiopathic cutaneous hyperchromia of the orbital region, periorbital melanosis, periorbital hyperpigmentation or infraorbital pigmentation, is a common condition frequently observed in dark-skinned patients, but has little data in scientific literature. We aimed to discuss our results of PRP procedure in the treatment of infraorbital dark circles using objective scales based on patient satisfaction and the quality of life.

**Methods:** Between 2016 and 2017, 9 patients complaining of infraorbital darkness were included who underwent 3 sessions of platelet-rich plasma injection. The outcome was determined by the difference in pre- and post- procedure FACE-Q modules which were designed as patient-reported outcome instrument to evaluate the unique outcomes of patients undergoing facial cosmetic procedures. Surveys conducted were modules of satisfaction with facial appearance, satisfaction with skin, psychological function, social function, aging appearance appraisal and satisfaction with outcome.

**Results:** All patients were followed up a minimum of 9 months. No major complications were recorded. Only transient ecchymosis and edema were seen in all patients who were improved during follow-up. The patient-reported FACE-Q satisfaction and FACE-Q quality of life pre- and post- procedure results showed statistically significant improvement (<0.05). Overall satisfaction with outcome was 83.33±16.25 (range 63–100).

**Conclusions:** PRP as a potent source of growth factors, can be seen as a safe, biocompatible, autologous and appropriate treatment modality for the dark eye circles formed in lower eye regions which can increase the quality of patients' lives in terms of social and psychological function.

**Keywords:** Dark circle, Hyperpigmentation, Infraorbital, Platelet-rich plasma

### INTRODUCTION

Infraorbital dark circles, also referred to as idiopathic cutaneous hyperchromia of the orbital region, periorbital melanosis, periorbital hyperpigmentation or infraorbital pigmentation, is a common condition frequently observed in dark skinned patients, but has little data in scientific literature.<sup>1</sup> Dark rings under the eyes are defined as

bilateral, round, homogeneous pigment macules over the infraorbital regions.<sup>2</sup> Dark circles can be caused by a variety of conditions such as infection, inflammation, allergies, and lifestyle factors.<sup>3</sup> Possible causative factors of the dark circles include excessive pigmentation; thin and translucent lower eyelid skin overlying the orbicularis oculi muscle; and shadowing due to skin laxity of aging and tear trough.<sup>3</sup> Excessive sun exposure,

drugs, hormonal causes and extension of pigmentary demarcation lines have also been considered to be contributory.<sup>1</sup> It worsens with aging and the process of skin sagging and altered subcutaneous fat distribution.<sup>4</sup> It has indeed a complex and little known pathophysiology makes challenging to treat.

Infraorbital dark circles may cause serious cosmetic problems, particularly in women, which may be the reason for their appearance as tired and old, and can affect their quality of life in terms of psychological and social aspects. The therapeutic approach of infraorbital dark circles varies according to the cause. In cases of excessive pigmentation, topical bleaching agents and chemical peels can be used. Lasers, fillers and autologous fat transplantation have proven to be successful in varying degrees. Although different methods for the treatment are available in the literature, most of the results are still unsatisfactory. New biological methods, such as platelet-rich plasma (PRP), may be promising in the treatment of infraorbital dark circles, as in other facial rejuvenation and aesthetic dermatology.

PRP is an autologous suspension of platelets in a small volume of plasma characterized by a platelet concentration above basal original blood values collected. PRP is used as a growth factor and cytokine pool which contains multiple angiogenic growth factors including platelet-derived growth factor (PDGF), transforming growth factor-beta (TGF- $\beta$ ), epidermal growth factor (EGF), vascular endothelial growth factor (VEGF), and fibroblast growth factor (FGF) for improving tissue regeneration in different fields of surgery and medicine.

A few studies have investigated the efficacy of PRP in the treatment of infraorbital dark circles.<sup>5-7</sup> Although the current studies have positive results, they could not aim to evaluate the change in the quality of life in those patients. In our study, we aimed to discuss our results of PRP procedure in the treatment of infraorbital dark circles using objective scales based on patient satisfaction and the quality of life. From this perspective, our study is the first in the literature measuring the effectiveness of the PRP with quality of life scales named FACE-Q in the treatment of infraorbital dark circles.

## **METHODS**

We investigated retrospectively 9 patients complaining of infraorbital darkness who underwent PRP injection procedure in the period from 2016 to 2017 in Plastic, Reconstructive and Aesthetic Surgery Clinic in Aydin State Hospital. Patient demographics were evaluated using patients' medical records. All protocols used in this study were performed according to the recommended International Regulations and Declarations and complied with the Declaration of Helsinki. This study was approved by the Local Medical Ethics Committee. All procedures were performed at outpatient clinics and all patients provided written informed consent.

The treatment course consisted of three sessions of autologous platelet-rich plasma injections into the dark eye circles in the infraorbital area with one month apart in between the injections and followed up for additional six months to assess the level of improvement or recurrence of the dark circles.

### **PRP preparation**

On the day of the procedure, 11 ml of whole blood was drawn into standard tubes containing anticoagulant citrate dextrose solution-formula A (ACD-A) with a blood to anticoagulant ratio of 9:1. We obtained 4 tubes for each patient (a mean of 44 ml of fresh blood from each patient). The 4 tubes were centrifuged for only 1 spin at a standard relative centrifugal force (RCF) of 1630 g for 5 min using a multipurpose centrifuge device (NF 800®, NUVE Industrial Materials Manufacturing and Trading Co., Turkey). Blood components were separated into the plasma, buffy coat, and erythrocyte layers. In our technique, the plasma layer formed after centrifugation is divided into approximately 3 equal portions, and the uppermost two-thirds is removed.<sup>8</sup> One-third of the plasma at the bottom and the buffy coat layer were collected without mixing these with the erythrocyte layer. Using this method, we obtained a mean of 1.2 ml of PRP from each tube (we collected approximately 4.8 ml of PRP from all 4 tubes without using any commercial kit systems). As a result of our previous clinical studies, baseline platelet concentrations increased 4-fold in the PRP using this manual technique. We do not activate PRP with calcium or thrombin since non-activated platelets present in PRP get gradually activated and secrete orchestrated growth factors up to 10 days.<sup>9</sup>

### **Assessment using FACE-Q scales**

The FACE-Q is a revolutionary patient-reported outcome instrument that evaluates specific outcomes in patients undergoing facial cosmetic procedures.<sup>10</sup> It utilizes several assessment scales to evaluate satisfaction with facial appearance, health-related quality of life, and satisfaction with the process of care. The FACE-Q satisfaction scales consist of questions relating to patient satisfaction with regard to facial appearance. Rating is performed based on the following scales: 1=very dissatisfied, 2=somewhat dissatisfied, 3=somewhat satisfied and, 4=very satisfied. Quality of life scales are rated as: "definitely disagree, somewhat disagree, somewhat agree, or definitely agree."<sup>10</sup>

*A pre-procedure FACE-Q was administered including the following modules*

- *Satisfaction with facial appearance:* This 10-item scale assesses the overall facial appearance using items including: "How your profile (side view) looks," "how fresh your face looks, and "how your face looks under bright lights."<sup>11</sup>

- *Satisfaction with skin:* This 12-item scale assesses facial skin in mind with items such as: “How your facial skin looks when you first wake up,” “how the tone (color) of your facial skin looks”.<sup>10</sup>
- *Psychological function:* This 10-item scale includes a series of positively worded statements that respondents are invited to agree/disagree, for example, “I feel good about myself,” “I feel confident,” “I feel attractive”.<sup>11</sup>
- *Social function:* This 8-item scale includes a series of positively worded statements that measure social confidence. Respondents are invited to agree/disagree with statements such as: “I make a good first impression,” “I am relaxed around people that I don’t know well”.<sup>11</sup>
- *Aging appearance appraisal:* This 7-item scale includes statements about how the patient feels about the age his-her face looks. Respondents may agree/disagree with statements such as: “I look older than I want to look,” “When I see my reflection, I am reminded of how old I look”.<sup>10</sup>

All patients included in this study completed a post-procedure FACE-Q at least 6 months after the last procedure. This questionnaire included the same modules as were assessed during pre-surgery evaluation but with the addition of a 6-item “satisfaction with outcome” module. Each FACE-Q scale was scored using a lookup conversion table approach. Scores range from 0–100 with higher scores indicating greater satisfaction and/or quality of life.<sup>10</sup> Results were grouped to obtain the mean pre- and post- procedure results.

**Statistical analysis**

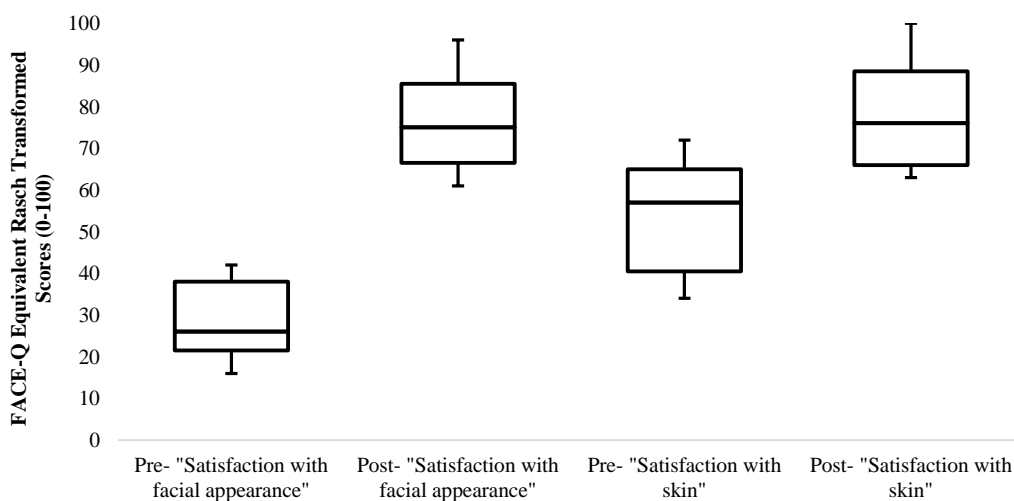
The SPSS (Statistical Package for Social Sciences, USA) 15.0 data analysis system was used for data analysis.

Normal distribution and homogeneity tests were performed on all data. Data are expressed as mean±standard deviation (SD). Statistical significance was calculated using the paired t-test if the data was approximately normally distributed and the variance was similar. If not, non-parametric tests were used for calculating statistical significance. Two-sided values of  $p < 0.05$  were considered statistically significant.

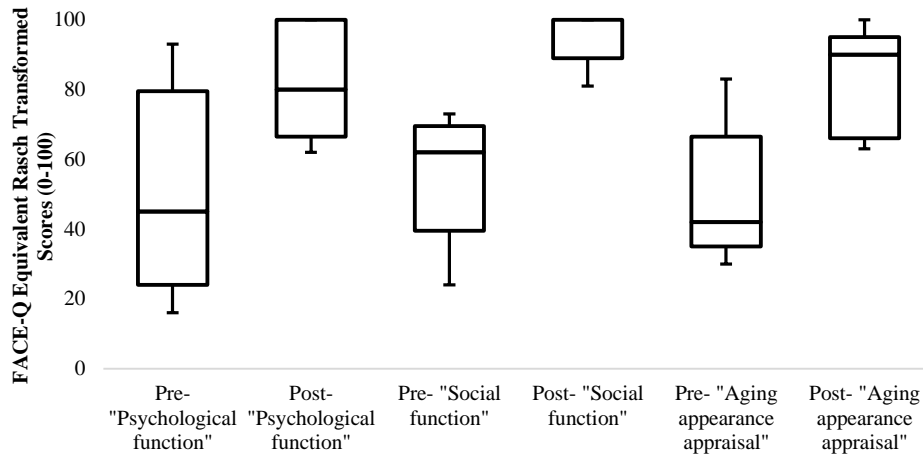
**RESULTS**

The mean age of the 9 patients included in this study was  $47.1 \pm 7.1$  years (range 38–63 years) and all were women. All patients were followed-up over a minimum period of 9 months. No major complications (e.g., infection, skin necrosis, nodulation, fibrosis, calcification, asymmetry, or vascular insults) were recorded. Only transient ecchymosis and edema were seen in all patients and all were improved during follow-up.

The patient-reported FACE-Q satisfaction (Figure 1) and FACE-Q quality of life scores (Figure 2) pre- and 6 months post-procedure after the last intervention showed a statistically significant improvement in all the FACE-Q modules assessed. Satisfaction with overall facial appearance improved from scores of  $28.9 \pm 8.9$  to  $80.1 \pm 11.96$  ( $p < 0.001$ , paired t-test) whereas satisfaction with the skin improved from scores of  $54.4 \pm 13.3$  to  $78.1 \pm 12.6$  ( $p < 0.05$ , paired t-test). Aging appearance appraisal improved from scores of  $50.2 \pm 18.7$  to  $83.1 \pm 14.6$  ( $p < 0.05$ , paired t-test). Social function and physiological function improved from scores of  $54.1 \pm 17.7$  to  $94.5 \pm 7.2$  and  $50.5 \pm 28.4$  to  $83.1 \pm 15.7$ , respectively (for both,  $p < 0.05$ ). Overall satisfaction with outcome was between 63 and 100 (Table 1). A few cases of pre- and post- PRP are illustrated in Figures 3-5.



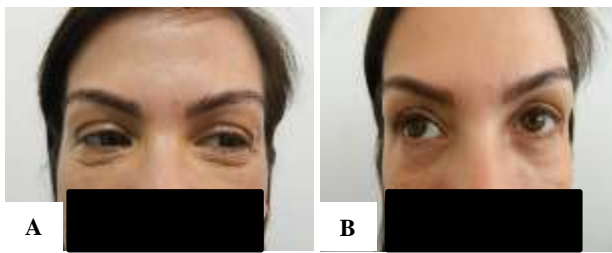**Figure 1: Graphic analysis of FACE-Q scores comparing pre- and post- procedure satisfaction of overall face and skin ( $p < 0.05$ ). Data represent group medians and quartiles with minimum and maximum scores. Lower scores represent a less satisfaction in the life with the face and skin. Changes in grading after the procedure can be seen.**



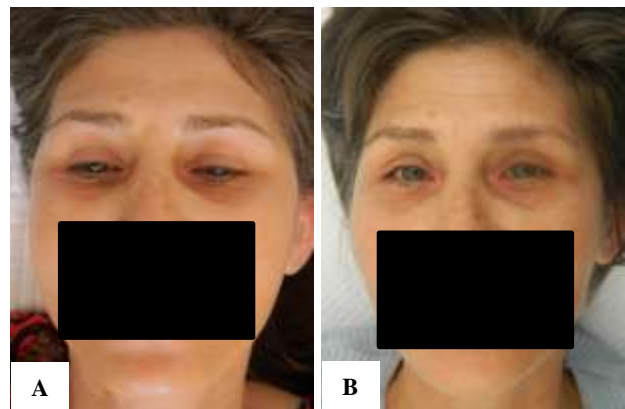
**Figure 2: The result of FACE-Q scores of quality of life comparing pre- and post- procedure psychological function, social function and aging appraisal (p<0.05). Data represent group medians and quartiles with minimum and maximum scores. Lower scores represent a less quality of life with facial appearance. Increased scores show the positive effects of the applied procedure on the social and psychological aspects of the patients’ lives.**

**Table 1: Patient overall satisfaction with the outcome of the PRP with FACE-Q at least 6 months after the last procedure.**

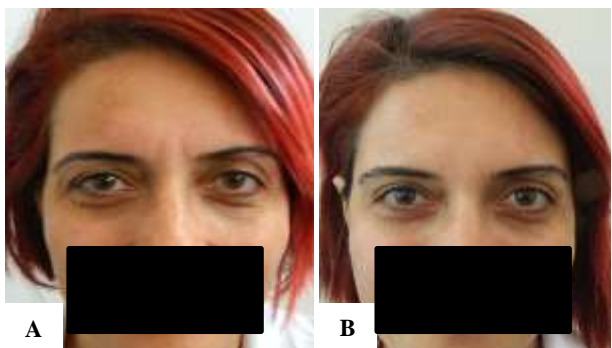	N	Minimum	Maximum	Mean	Std. Deviation
<b>Satisfaction with outcome</b>	9	63.00	100.00	83.33	16.25



**Figure 3: (A) A patient with infraorbital dark eye circles; (B) 6 months after the last PRP procedure. The skin of the infraorbital region was improved with a good to excellent manner.**



**Figure 5: (A) A patient with infraorbital dark eye circles; (B) 15 months after the last PRP procedure shows a stable improvement in the infraorbital area. The fatigue expression has been no longer noticed.**



**Figure 4: (A) A patient with infraorbital dark eye circles; (B) 9 months after the last PRP procedure shows us a moderate improvement. It should be noticed that the sleepy image was disappeared.**

**DISCUSSION**

There are two types of dark eye circles: those of predominantly vascular aetiology and those of predominantly melanic aetiology.<sup>12</sup> The majority, however, have mixed origins and are caused by the combination of the pigments melanin and hemosiderin.<sup>12</sup> Dark circles based on predominantly vascular origin present a dominant autosomal genetic transition, whereas dark circles based on melanic origin are more frequently seen in older patients with higher phototypes.<sup>12</sup> The

increase of melanin at dark eye circles can be observed in older subjects and in excessive sun contact.<sup>12,13</sup> In addition, it was also reported that the use of hormonal replacement therapy and contraceptives, and menstruation and pregnancy can worsen dark eye circles due to the hormonal stimulus of melanin production.<sup>12</sup>

Clinically, dermal melanocytoses are gray or blue-gray in colour as a consequence of the color transmission of black pigment through the dermis. If they are located infraorbitally, they can be a cause of dark circles under the eyes.<sup>14</sup> Watanabe et al studied periorbital biopsies of Japanese patients with infraorbital dark circles, showing that all had dermal melanosis in the histology.<sup>14,15</sup> According to a study conducted by Kikuchi et al, women with dark circles showed larger amounts of melanin, and lower haemoglobin oxygen saturation ratio and the skin lightness in the lower eyelids than subjects without dark circles.<sup>16</sup> They confirmed that dark circles could be improved by using an anti-dark circle cosmetic as evaluated by visualizing the distribution of melanin concentration and haemoglobin oxygen saturation ratio, which are the factors that induce dark circles.<sup>16</sup> Concerning haemoglobin oxygen saturation and blood flow rate circulation in the eyelids, Masuda et al reported that an increased amount of haemoglobin and decreased haemoglobin oxygen saturation were observed at the site of dark eye circles.<sup>13</sup> Blood flow stagnation seems to be one of the factors that could induce dark eye circles. It was also reported that a deficiency in vitamin K, vital in the blood coagulation process, can cause small haemorrhages and cause dark eye circles.<sup>12</sup> On the basis of those results, it is tempting to speculate that congestive vessels which can be the result of decreased oxygen saturation and can cause extravascular haemoglobin escape and hemosiderin accumulation constitutes the pathophysiology of this cosmetic problem. Besides that, it is considered that not only congestion but also an increase of melanin content in the skin may induce dark eye circles. So, dark circles treatment should include improving blood circulation and reducing melanin content with increasing extracellular matrix in the skin.

PRP has become popular and used as a rich suspension of fundamental growth factors proved to be actively secreted by platelets in the last three decades. Receptors for growth factors in PRP are found on adult mesenchymal stem cells, fibroblasts, osteoblasts, endothelial cells, and epidermal cells.<sup>17</sup> PRP is more than just a growth factor concentrate; it also contains the 3 proteins in blood known to act as cell adhesion molecules for connective tissue, and epithelial migration.<sup>17</sup> As an autologous source of growth factors and cytokines, PRP is completely biocompatible and has therefore gained popularity as a safe and natural healing therapy.

Fibroblasts are the most common cell type in the dermis and the most influential cells in production of collagen and other extracellular components. Fibroblasts are strongly reactive to fibroblast growth factor-beta, platelet

derived growth factor and epidermal GF. Cho et al demonstrated that PRP induced increases in cell migration, and proliferation rates, as well as an increase in the expression of G1 cell cycle regulatory proteins, such as cyclin A, Cdk2, and cyclin E in human skin fibroblasts.<sup>18</sup> In this study, treatment of human skin fibroblasts with PRP resulted in increased expression of type I collagen by matrix metalloproteinases I and II which promote remodelling of extracellular matrix and facilitating cell migration.<sup>18</sup>

Kim et al investigated the effects of TGF-beta1 on melanogenesis using a spontaneously immortalized mouse melanocyte cell line.<sup>19</sup> They showed that TGF-beta1 significantly inhibited melanin synthesis in a concentration-dependent manner and that it reduced the activity of tyrosinase, the rate-limiting melanogenic enzyme.<sup>19</sup> On the other hand, Yun et al investigated the role of EGF in melanogenesis by search for expression of EGFR on melanocytes and the effect of EGF on melanin production by melanocytes with or without laser-treated keratinocyte-conditioned culture media.<sup>20</sup> Melanocytes treated with laser-treated keratinocyte-conditioned culture media had greater prostaglandin-E2 (PGE2) expression and tyrosinase enzyme activity than melanocytes treated with control media, and treatment with EGF lowered melanin production of melanocytes of laser-treated keratinocyte-conditioned culture media but not of melanocytes treated with control media.<sup>20</sup> So, it could be argued that some growth factors, such as the two, may reduce the synthesis of melanin through tyrosinase or some other mechanisms in melanogenesis.

Al-Shami studied the effectiveness of platelet-rich plasma in the treatment of periorbital hyperpigmentation and reported as follows: two patients (4%) reported excellent improvement, six patients (12%) significant improvement, twenty three patients (46%) moderate improvement, and nineteen patients (38%) mild improvement in the appearance of the dark circles.<sup>7</sup> In that study, the patients were asked to evaluate their own level of satisfaction by giving themselves a score from 0-4 points and the score was translated into a range from no change to excellent. In a case report, melasma was also reported to be successfully treated with PRP with an observation of >80% reduction in epidermal hyperpigmentation.<sup>21</sup> However, it was not reported what the scale they used for the observation.<sup>21</sup>

In a split-face study, Nofal et al compared the efficacy and safety of PRP and the carboxytherapy in the treatment of periorbital hyperpigmentation by patient satisfaction on a 1-3 scale: 1 = slightly satisfied, 2 = moderately satisfied, and 3 = well satisfied.<sup>4</sup> They found that the improvement was comparable with no statistically significant difference between both modalities and both PRP and carboxytherapy are relatively effective.<sup>4</sup> In another study, Mehryan et al used almost the same scale for the assessment of satisfaction, and reported that participant's satisfaction score and



physician's global assessment score were 2.2 and 1.7, respectively, on a 0–3 scale.<sup>5</sup>

As seen, there are a few studies reporting the use of PRP on dark eye circles.<sup>4,5,7,21</sup> In addition, the methodology of evaluating patient satisfaction in these existing studies remains quite weak. We used FACE-Q in our patients before and after application for the assessment. The FACE-Q is a patient-reported outcome instrument that measures the experience and outcomes of aesthetic facial procedures from the patient's perspective giving unprecedented insight into their satisfaction and health-related quality of life.<sup>10</sup> In procedures aiming at aesthetic improvement, patient perception of the treatment outcome appears to be most important because it has a direct impact on patients' body image and self-esteem.<sup>22</sup>

Some aspects of our study may be seen as remarkable. The evaluation of satisfaction with facial appearance and skin before and after the procedure makes it clearer how much the dark eye circles affect the facial appearance and skin satisfaction in patients. While the social and psychological function assessments were examined, it was observed that the quality of life of the patients had changed after the treatment with PRP for dark eye circles. It can be added that dark eye circle treatment with PRP even contributes to the increased quality of patient-perceived age feeling. When the satisfaction with outcome is examined, the satisfaction of the patients from the PRP procedure for the treatment of the dark eye circles was observed to be a score of 83 within the range of 0-100 and could be interpreted as a good satisfaction level.

As a conclusion, in our study, we demonstrated the patient-based effects of dark eye circles before and after treatment with PRP procedure. Our study is different from other studies in this aspect and it may be classified as the first study that evaluates the effectiveness of PRP in dark eye circles by evaluating and comparing the patient's quality of life as before and after. PRP as a potent source of growth factors, can be seen as a safe, biocompatible, autologous and appropriate treatment modality for the dark eye circles formed in lower eye regions which has a thin skin that can increase the quality of patients' lives in terms of social and psychological function.

*Funding: No funding sources*

*Conflict of interest: None declared*

*Ethical approval: The study was approved by the institutional ethics committee*

## REFERENCES

1. Sarkar R. Idiopathic cutaneous hyperchromia at the orbital region or periorbital hyperpigmentation. *J Cutan Aesthet Surg.* 2012;5(3):183-4.
2. Freitag FM, Cestari TF. What causes dark circles under the eyes? *J Cosmet Dermatol.* 2007;6(3):211-5.
3. Park SR, Kim HJ, Park HK, Kim JY, Kim NS, Byun KS, et al. Classification by causes of dark circles and appropriate evaluation method of dark circles. *Ski Res Technol.* 2016;22(3):276-83.
4. Nofal E, Elkot R, Nofal A, Eldesoky F, Shehata S, Sami M. Evaluation of carboxytherapy and platelet-rich plasma in treatment of periorbital hyperpigmentation: A comparative clinical trial. *J Cosmet Dermatol.* 2018;17(6):1000-7.
5. Mehryan P, Zartab H, Rajabi A, Pazhoohi N, Firooz A. Assessment of efficacy of platelet-rich plasma (PRP) on infraorbital dark circles and crow's feet wrinkles. *J Cosmet Dermatol.* 2014;13(1):72-8.
6. Ahmed NA, Mohammed SS, Fatani MI. Treatment of periorbital dark circles: Comparative study of carboxy therapy vs chemical peeling vs mesotherapy. *J Cosmet Dermatol.* 2018;1:1-7.
7. Al-Shami SH. Treatment of periorbital hyperpigmentation using platelet-rich plasma injections. *Am J Dermatol Venereol.* 2014;3(5):87-94.
8. Ozer K, Kankaya Y, Çolak Ö. An important and overlooked parameter in platelet rich plasma preparation: The mean platelet volume. *J Cosmet Dermatol.* 2018.
9. Atashi F, Jaconi MEE, Pittet-Cuénod B, Modarressi A. Autologous platelet-rich plasma: a biological supplement to enhance adipose-derived mesenchymal stem cell expansion. *Tissue Eng Part C Methods.* 2015;21(3):253-62.
10. A revolutionary patient-reported outcome instrument by Memorial Sloan-Kettering Cancer Center:FACE-Q. Available at: <http://qportfolio.org/faceq/>. Accessed on 3 February 2019.
11. East C, Badia L, Marsh D, Pusic A, Klassen AF. Measuring Patient-Reported Outcomes in Rhinoplasty Using the FACE-Q: A Single Site Study. *Facial Plast Surg.* 2017;33(5):461-9.
12. Souza D, Ludtke C, Souza ERM, Scandura KMP, Weber MB. Periorbital hyperchromia. *Surg Cosmet Dermatol.* 2011;3(3):233-9.
13. Masuda Y, Takahashi M, Satou A. Dermatological Study on Dark Eye Circles and Their Treatment with Newly Developed Cosmetics. *J Soc Cosmet Chem Japan.* 2004;38(3):202-10.
14. Roh MR, Chung KY. Infraorbital dark circles: definition, causes, and treatment options. *Dermatol Surg.* 2009;35(8):1163-71.
15. Watanabe S, Nakai K, Ohnishi T. Condition known as "dark rings under the eyes" in the Japanese population is a kind of dermal melanocytosis which can be successfully treated by Q-switched ruby laser. *Dermatol Surg.* 2006;32(6):785-9.
16. Kikuchi K, Masuda Y, Hirao T. Imaging of hemoglobin oxygen saturation ratio in the face by spectral camera and its application to evaluate dark circles. *Skin Res Technol.* 2013;19(4):499-507.

17. Marx RE. Platelet-rich plasma: evidence to support its use. *J Oral Maxillofac Surg*. 2004;62(4):489-96.
18. Cho JW, Kim SA, Lee KS. Platelet-rich plasma induces increased expression of G1 cell cycle regulators, type I collagen, and matrix metalloproteinase-1 in human skin fibroblasts. *Int J Mol Med*. 2012;29(1):32-6.
19. Kim DS, Park SH, Park KC. Transforming growth factor-beta1 decreases melanin synthesis via delayed extracellular signal-regulated kinase activation. *Int J Biochem Cell Biol*. 2004;36(8):1482-91.
20. Yun WJ, Bang SH, Min KH, Kim SW, Lee MW, Chang SE. Epidermal growth factor and epidermal growth factor signaling attenuate laser-induced melanogenesis. *Dermatol Surg*. 2013;39(12):1903-11.
21. Cayırlı M, Çalışkan E, Açıkgöz G, Erbil AH, Ertürk G. Regression of melasma with platelet-rich plasma treatment. *Ann Dermatol*. 2014;26(3):401-2.
22. Al-Saedy SJ, Al-Hilo MM, Al-Shami SH. Treatment of acne scars using fractional Erbium: YAG laser. *Am J Dermatol Venereol*. 2014;3(2):43-9.

**Cite this article as:** Ozer K, Colak O. Evaluation of platelet-rich plasma on infraorbital dark circles by using the FACE-Q scales. *Int J Res Dermatol* 2019;5:xxx-xx.